



**PATIENT**

Hunter Moran Cisneros

**SPECIES**

Feline

**BREED**

DSH

**SEX**

Male Neutered

**AGE**

7 years

**WEIGHT**

15.1lbs

**INTERPRETED BY**

Maggie Machen Lamy,  
DVM DACVIM  
(Cardiology)

**IMAGING PERFORMED BY**

Kelly Reschny, RVT

**HOSPITAL NAME**

Downton Animal  
Hospital

**REFERRING VET**

Dr. Ahn

**INVOICE**

46910

**DATE**

2/19/26

**PRESENTING CLINICAL SIGNS**

History: Presented for general malaise, not eating, coughing/non-productive hacking. Started on Cerenia, Gabapentin, Mirtazapine. Elevated BNP.

-Abnormal PE/Chem/CBC/UA Results (2/9/26): BNP: abnormal. CBC, chem 17, SDMA, FIV/FelV - no abnormalities except mild low PHOS.

**ECHOCARDIOGRAM FINDINGS**

2D, m-mode, color flow and doppler imaging is available. The left ventricular wall is normal in dimension. The LV chamber is normal in dimension. There is a mildly hyperechoic endocardium consistent with fibrosis. The papillary muscles are mildly remodeled. The LV systolic function is mildly depressed. The left atrium is significantly dilated and bulbous in appearance with a horizontal component. No spontaneous contrast visualized. The right atrium appears normal. The mitral valve appears mildly thickened with no significant MR. The TV appears normal with no TR. Blood flow through the LVOT and RVOT are normal in velocity. Scant pericardial effusion. No pleural effusion. No obvious cardiac tumors.

**CARDIAC CHART**

FELINE CARDIAC PARAMETERS	BODY WEIGHT (kg)	HR (BPM)	IVSd (cm) (Moise, Pipers)	LVIDd (cm) (Moise, Pipers)	LVWd (cm) (Moise, Pipers)	FS (%)	EF (%)
<b>NORMAL PARAMETER</b>	-----	150-240	0.35-0.55	<2 (mean 1.5)	3.5-0.55	35-67	80-100
<b>PATIENT</b>	6.9	120	0.52	1.5	0.50	37	71
FELINE CARDIAC PARAMETERS	LA/AO (Boon)	LA/AO HEART BASE (Swe) (Abbott)	LA 2D short axis Base view (cm) (Abbott)		LVOT VEL (m/s)	RVOT VEL (m/s)	E max (m/s)
<b>NORMAL</b>	<1.5	<1.3	<1.2		<1.6	<1.3	<0.9
<b>PATIENT</b>	2.2	2.2	1.9		0.7	0.6	NM
<p><i>*Note: All measurements based upon multi-modal images and methods. An average value is reported.</i> Adapted from June Boon, Veterinary Echocardiography, 1998 Abbott J &amp; MacLean H JVIM 2006;20: 111-119, Moise et al. Am J Vet Res 47:1476, 1986. Pipers et al. Am J Vet Res 40:882, 1979.</p>							

**INTERPRETATION OF THE FINDINGS & FURTHER RECOMMENDATIONS**

The finding of severe left atrial enlargement in the face of normal LV wall thickness with mild LV dysfunction is most consistent with Unclassified Cardiomyopathy; however, other categorical classifications cannot be ruled out. No hypertrophy is seen, ruling out typical hypertrophic disease. The right heart appears normal, and no additional Issues are identified.

Regardless, what is seen here is severe and puts the patient at high risk for CHF. Given scant pericardial effusion, the patient is in early CHF and full lifelong supportive medications should be instituted as below.



**PATIENT**

Hunter Moran Cisneros

**SPECIES**

Feline

**BREED**

DSH

**SEX**

Male Neutered

**AGE**

7 years

**WEIGHT**

15.1lbs

**INTERPRETED BY**

Maggie Machen Lamy,  
DVM DACVIM  
(Cardiology)

**IMAGING PERFORMED BY**

Kelly Reschny, RVT

**HOSPITAL NAME**

Downton Animal  
Hospital

**REFERRING VET**

Dr. Ahn

**INVOICE**

46910

**DATE**

2/19/26

The mean survival time for cats with severe disease is <1 year; however, most are able to maintain a good quality of life on medications if tolerated.

Going forward, there will always remain risk for recurrent episodes of CHF and development of blood clots in the future. Monitoring of sleeping breathing rates at home is recommended as the best way to screen for recurrent CHF at home.

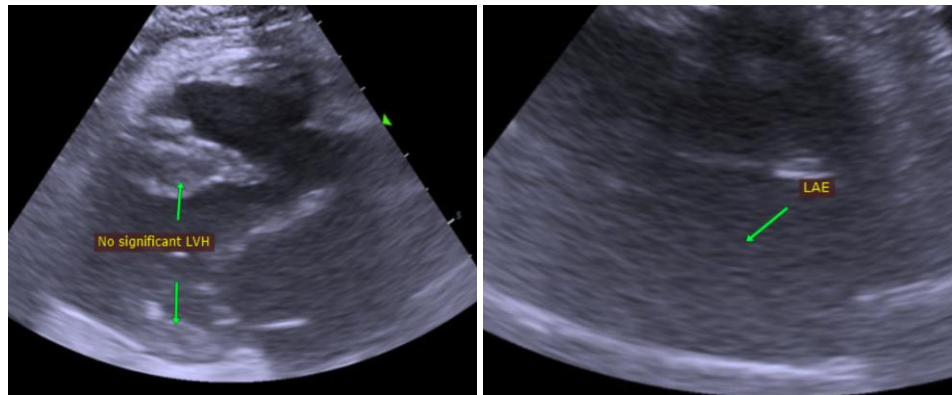
**PLAN**

Baseline BP is recommended. Institute low dose Lasix 1mg/kg PO q12h. Institute blood thinner Clopidogrel (Plavix) 75mg tablets; give ¼ tab orally once daily (NOTE: this medication is very bitter on the cut edges). Institute Pimobendan 1.25mg PO q12h (off label use). If able to adequately medicate, institute ACE-I 0.5mg/kg PO q12h.

Monitor renal values and BP in 1-2 weeks then every 3-4 months lifelong.

A recheck echocardiogram is recommended in 6 months to screen for progression.

**IMAGES**



**The information and recommendations provided are based on the images presented by the referring veterinarian. No evaluation can be communicated regarding pathology that was not visible in the image/video clips provided.**

Thank you for this referral. This report was generated using transcription software, and minor dictation errors may be present. If the clinical or image interpretation does not parallel your findings or if I can be of any further assistance, please contact me.

**Maggie Machen Lamy, DVM**  
**Diplomate of the American College of Veterinary Internal Medicine (Cardiology)**  
info@sonopath.com